

TESTING A QUICK AND RELIABLE METHOD TO DISCRIMINATE AGE CLASSES IN ROE DEER *CAPREOLUS CAPREOLUS* ON THE BASIS OF TOOTH WEAR

LUCIANO CICOGNANI AND FRANCA MONTI

ST.E.R.N.A., via Pedriali 12, 47100 Forlì, Italy

ABSTRACT - The hunting management of roe deer in Emilia-Romagna provides the correct classification of the age classes of dead specimens, usually determined shortly after killing by hunters. The tricuspidal shape of the third lower premolar, together with the absence of the third molar greatly facilitates the classification of fawns (class 0); whereas distinguishing between yearlings (class I) and adults (class II) is very difficult, particularly in females. This paper proposes a reliable method that entails just a quick tooth inspection of the lingual crest of the third lower premolar and molar. In yearlings they were completely covered by a coat of enamel, whereas in adults this coat of enamel was eroded, so that a yellowish line of dentin, that tended to become wider with age, was clearly visible. The first lower molar of specimens previously classified on the basis of tooth wear were decalcified and dissected so that the number of annual growth rings could be counted using a microscope. By doing this, we could test the validity and reliability of our method. Fifty four specimens, 39 belonging to class I and 15 to class II, were examined and in all cases the method allowed a correct classification.

Key words: dentine, enamel, dental table, growth rings, age classes, *Capreolus capreolus*, Italy.

INTRODUCTION

The age class of roe deer, killed by hunters, is usually determined by technicians on the basis of the lower jaw features. The tricuspidal shape of the lower third premolar tooth, together with the absence of the lower third molar, makes it easy to classify fawns (class 0), whereas especially among females, discrimination between yearlings (class I) and adults (class II) is more difficult. On the other hand, the correct discrimination between class I and class II is of great importance for hunting management, since the number of class I, apart from natural mortality among adults, coincide with the sustainable yield of a population on a yearly basis, thus making it necessary to assess the actual hunting bag in this age class correctly each year, to decide on successive hunting plans.

MATERIAL AND METHODS

In this paper we suggest a reliable method, requiring just a quick examination, to discriminate between class I and class II roe deer. To this aim the teeth of 18 male roe deer killed by hunters during 1997 and previously classified as class I on the basis of antler development and characteristics, were evaluated. We observed that the lingual crest of the third lower premolar as well as of the third lower molar - i.e. the two last permanent teeth to erupt - at the age of 12-14 months (Tarello, 1991; Perco and Perco, 1980), were completely covered by a coat of enamel (Fig. 1). On the contrary, in a large part of the specimens previously classified as class II, this coat of enamel was eroded, so that a yellowish line of dentin, that tended to become wider with age, was clearly visible (Fig. 1). At this stage another 36 spe-

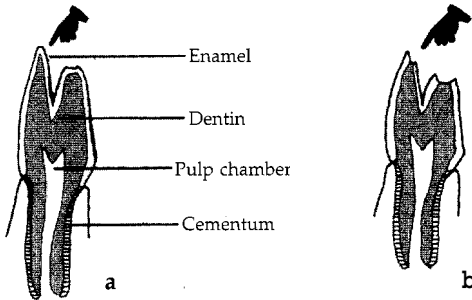


Figure 1 - Lower third premolar of (a) yearlings with intact enamel coat, and (b) of adults with eroded enamel coat.

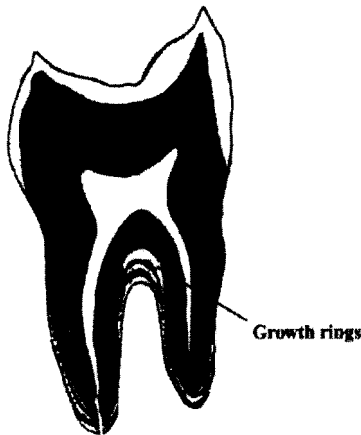


Figure 2 - Tooth section showing growth rings.

Table 1 - Presence of dentin in the lingual crest of third lower premolar and of third molar, in the 54 specimens analysed.

Age (years) specimens	N° of	Sex	Presence
1	21	F	Not detectable
1	18	M	Not detectable
2	10	F	Visible
2	3	M	Visible
3	2	F	Visible

Table 2 - Presence of dentin in the lingual crest of the third lower premolar and of the third molar

Age (years)	N° of specimens	Presence
1	39	Not detectable
2-3	15	Visible

cimens were evaluated and classified using the visual method described, selecting among specimens classified as class II those showing a degree of wear similar to the specimens classified as class I. The next step was to determine the actual age of the examined specimens through the observation of incremental lines - i.e. growth rings (Mitchell, 1967). The observation was made sectioning the first lower molar, since being the earliest permanent tooth to erupt at the age of 2-3 months, the growth rings are more clearly observable (Tarello, 1991). After partial decalcification using potassium hydrate to soften the gum thus facilitating the extraction of the tooth, a diagonal cut was made following the line that separates the fore cuspid from the back one (Fig. 2). Using very thin texture sandpaper we made the surface of the section smooth and uniform. The growth rings were evaluated using a low magnification microscope.

RESULTS

The age determination obtained from the observation of the growth rings, totally confirmed the visual classification previously made (Tables 1, 2). In order to confirm the

REFERENCES

- Bow, J.M. and Purday, C., 1996. A method of preparing sperm whale teeth for age determination. *Nature, Lond.*, 210: 437-438.
- Erickson, J.A. and Seliger, W.G., 1969. Efficient sectioning of incisor for estimating ages of mule deer. *J. Wildl. Manage.*, 33: 384-388.
- Mitchell, B., 1967. Growth layers in dental cement for determining the age of red deer (*Cervus elaphus* L.). *J. Anim. Ecol.*, 36: 279-293.
- Morris, P., 1972. A review of mammalian age determination methods. *Mammal Rev.*, 2: 69-104.
- Perco, F. and Perco, D., 1980. *Il Capriolo*. Ed. Carso, Trieste.
- Ransom, A.B., 1966. Determining age of white-tailed deer from layers in cementum of molars. *J. Wildl. Manage.*, 30: 197-199.
- Tarello, W., 1991. *Il Cervo e il Capriolo*. Storia naturale, comportamento, ecologia, miti e leggende, patologia e gestione. Regione Autonoma Valle d'Aosta. Museo regionale di Scienze Naturali Saint-Pierre (Aosta). Musumeci, Aosta.